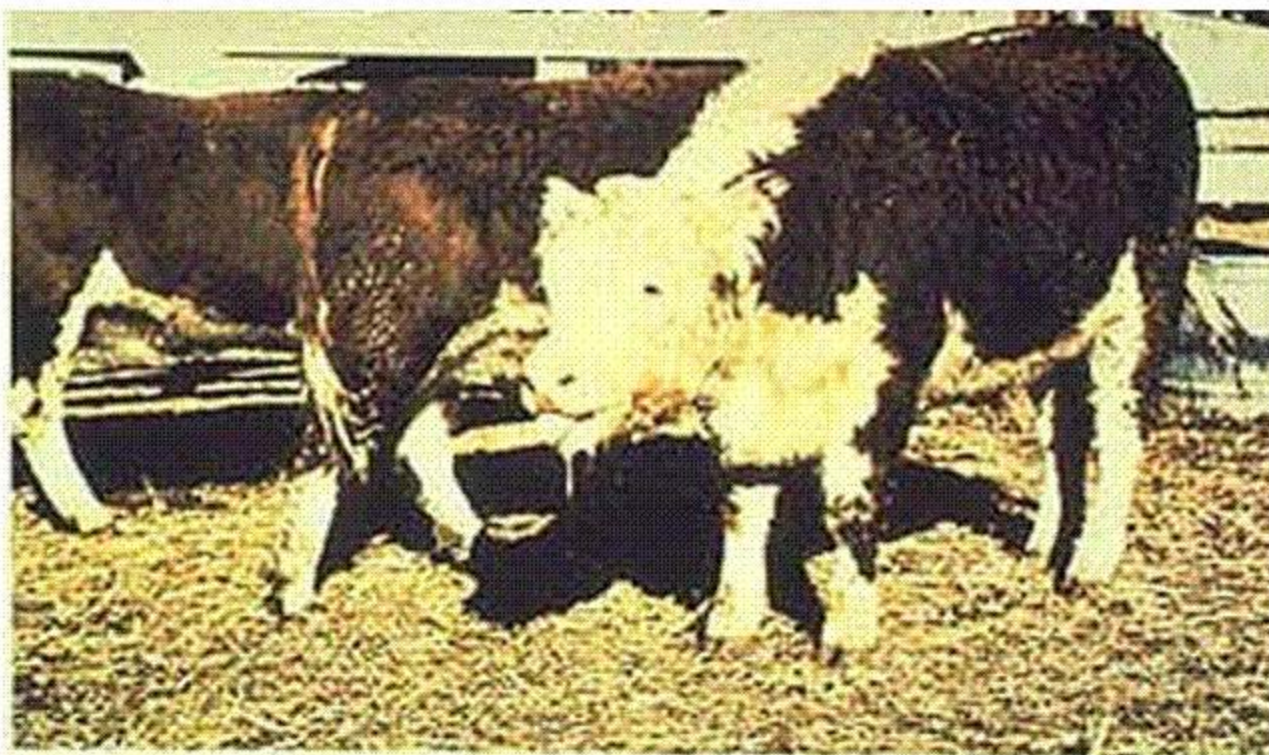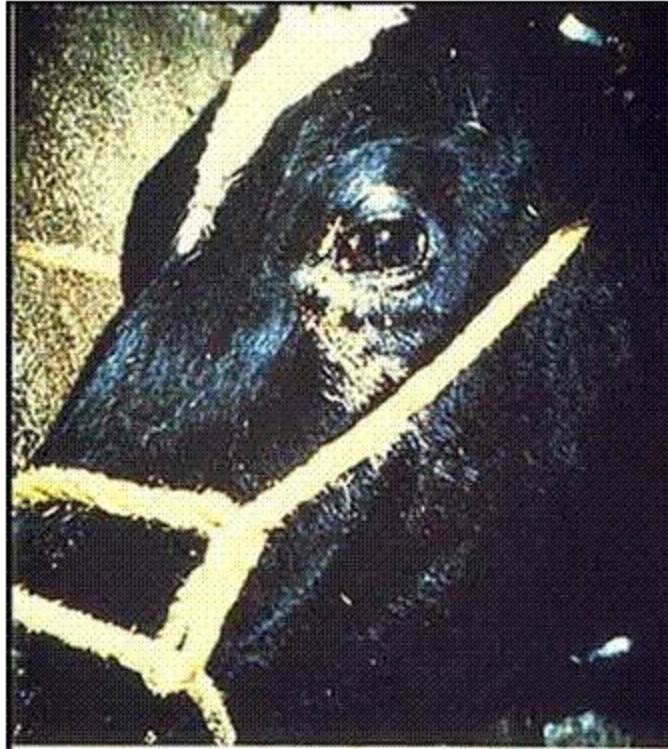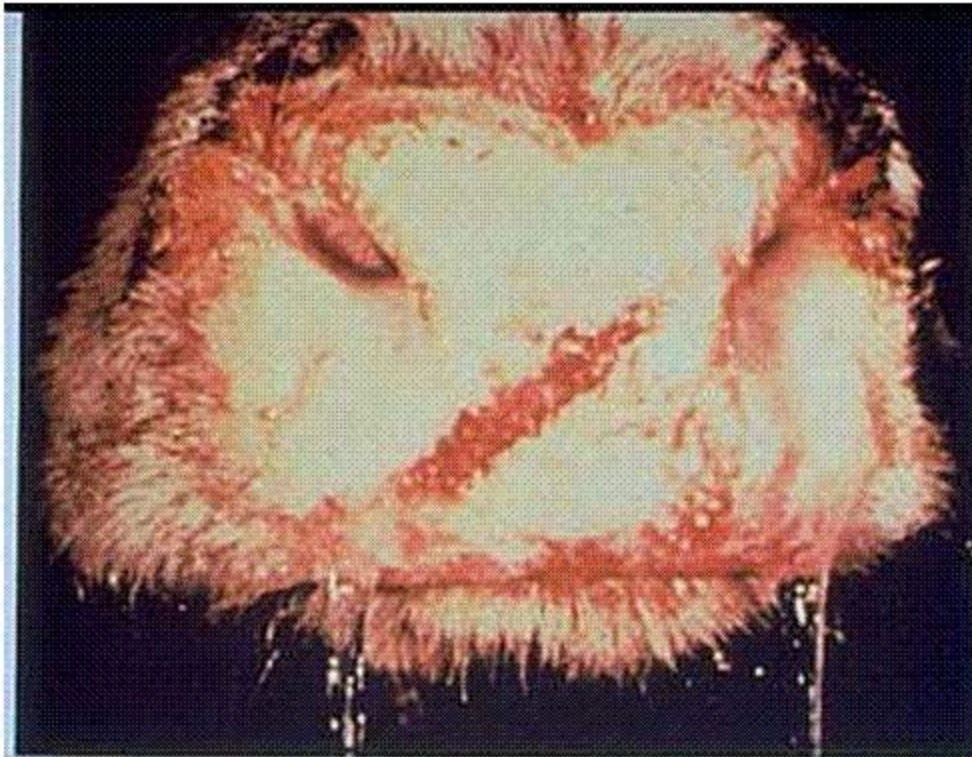


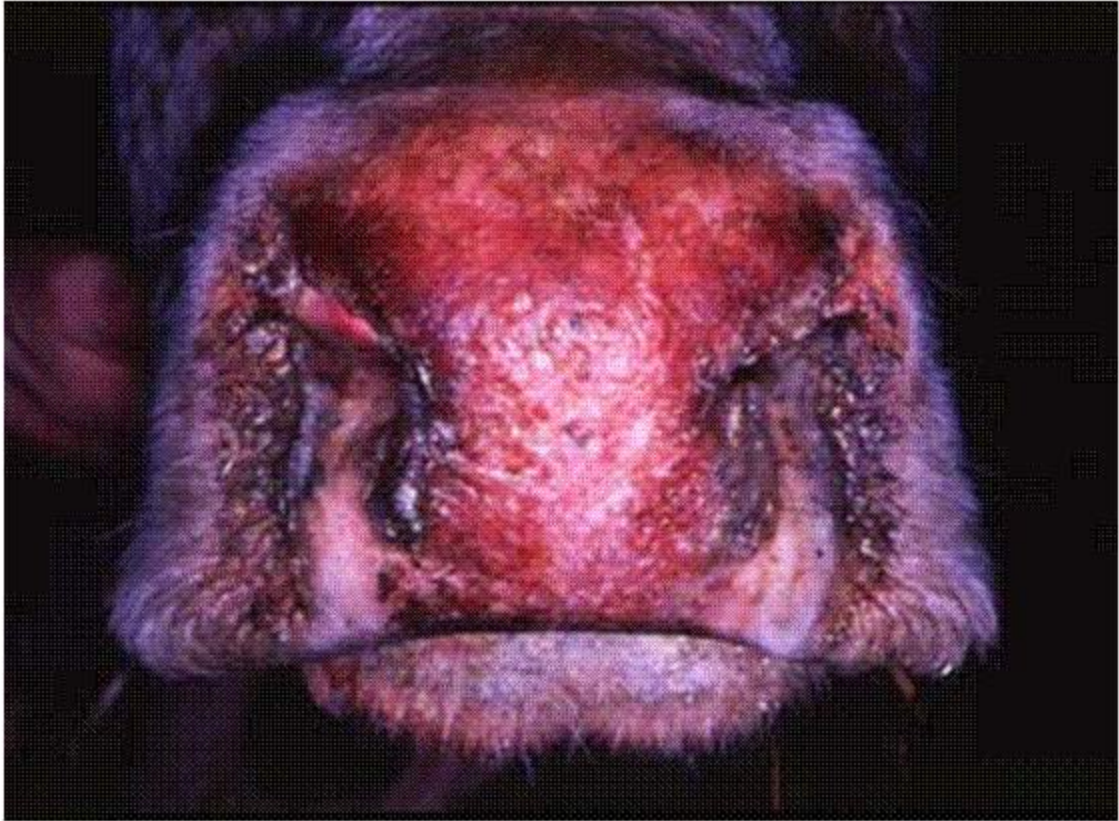**1 Breathing through the mouth and salivation in a bovine with IBR.**

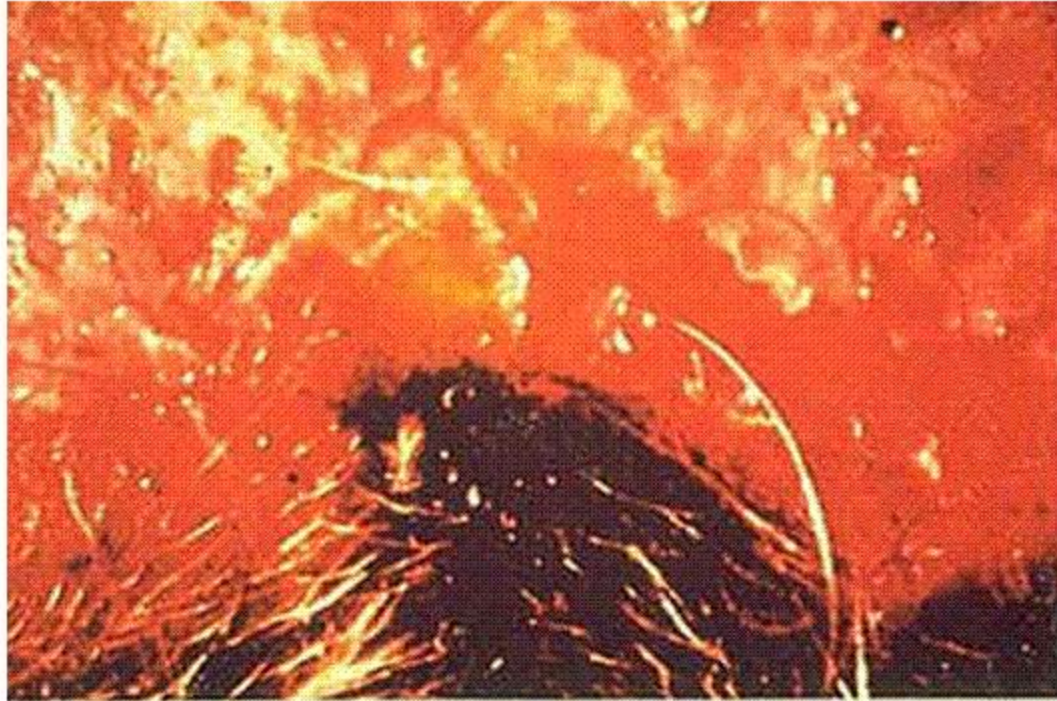

2 Ocular discharge (IBR).

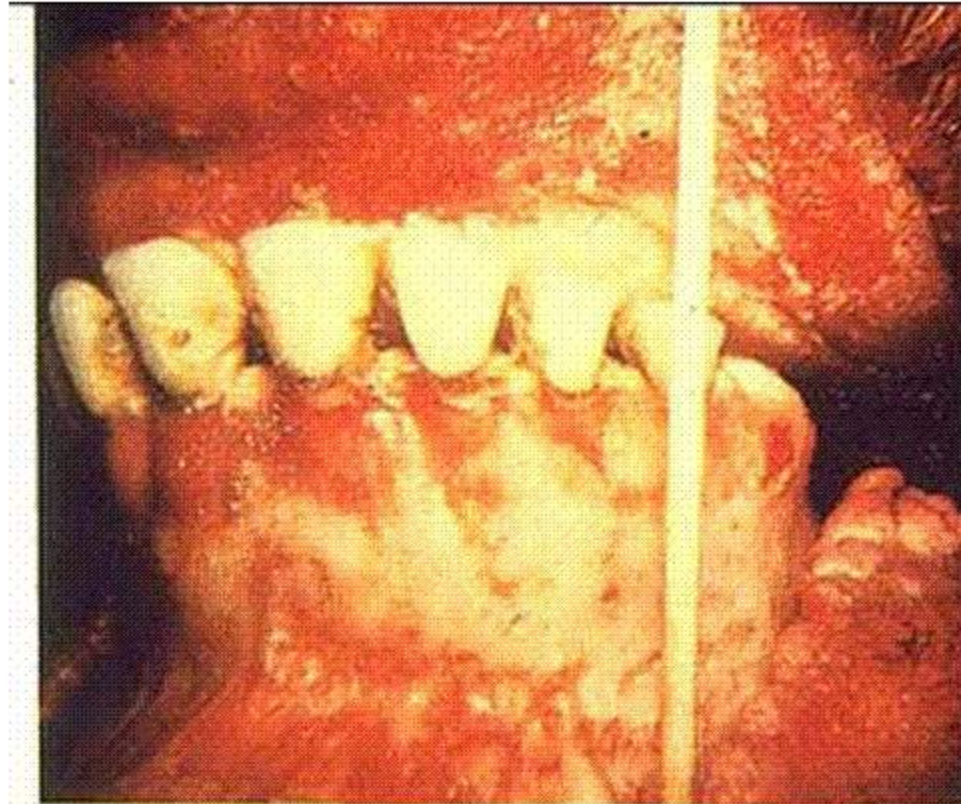


3 Copious nasal discharge with hemorrhage and congestion of the muzzle (IBR).

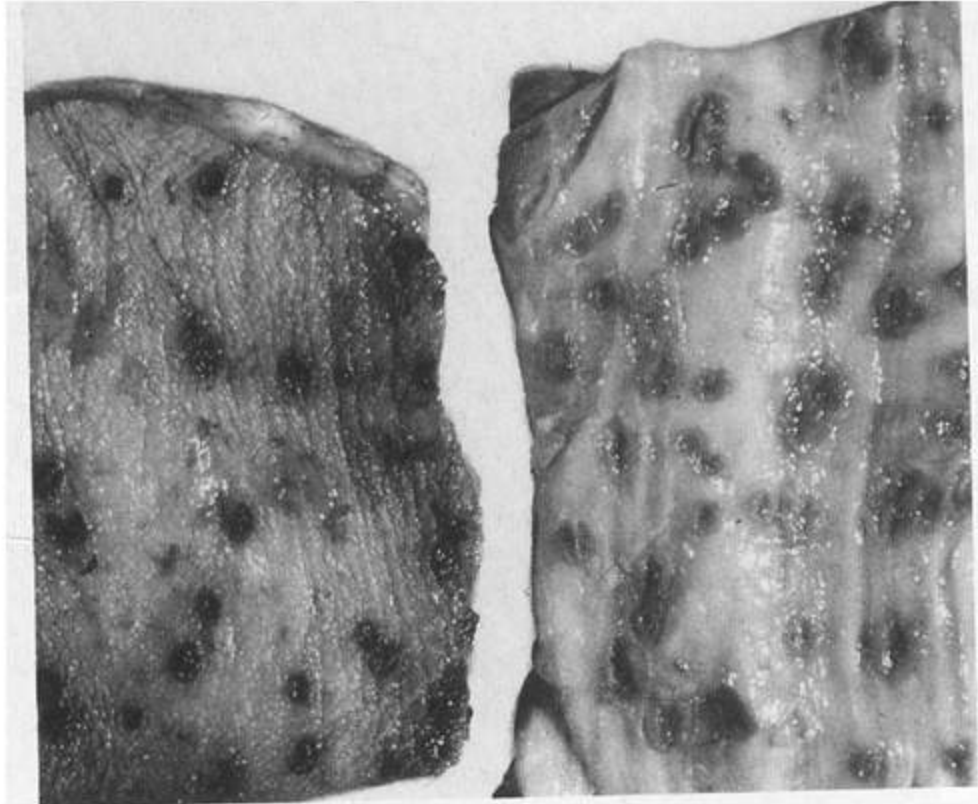




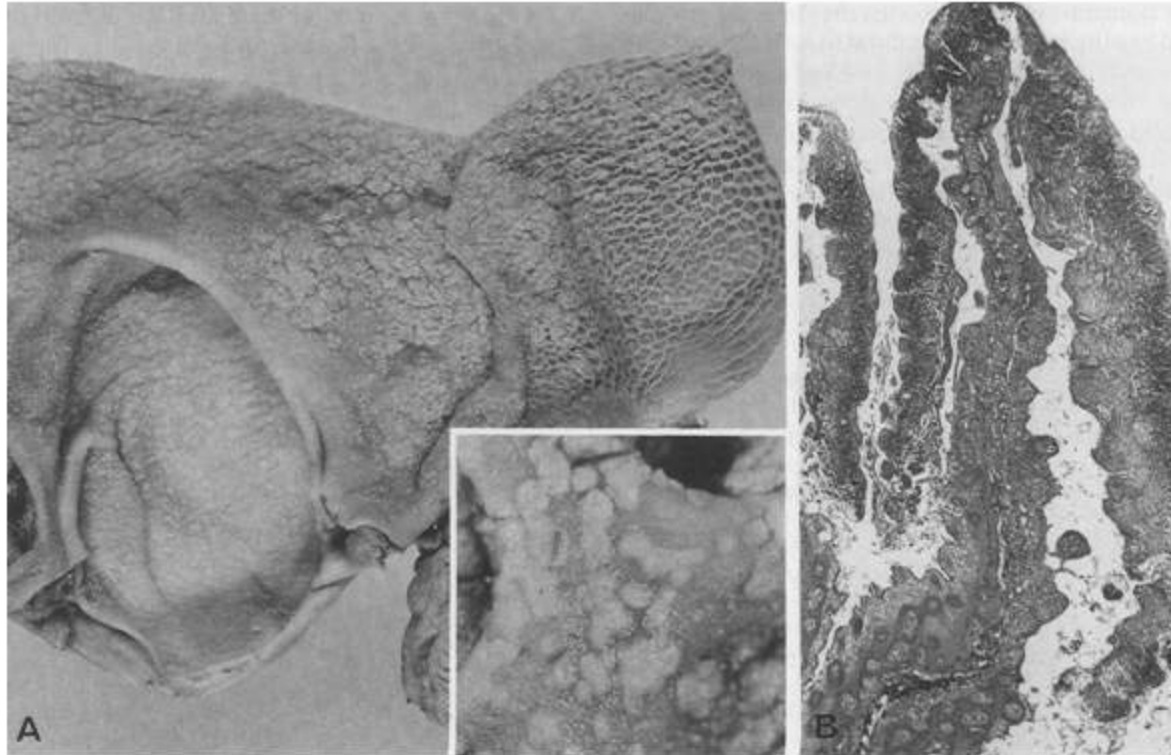
4 Close-up view of erosive lesions and diffuse hemorrhages around the muzzle-"red nose" (IBR).



**5 Hemorrhages and erosions in the buccal mucosa and gums (IBR).**



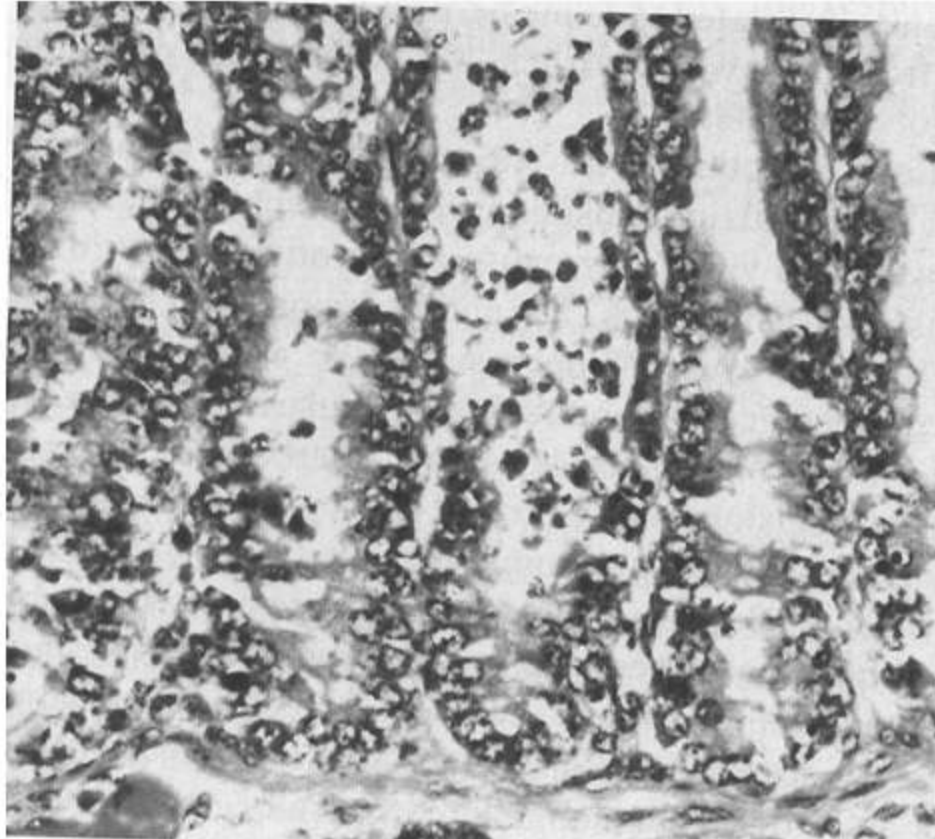
**IBR. Foci of necrosis on mucosa of esophagus and rumen.**



**Cheesy necrotic debris in rumen and reticulum (IBR).**

**Necrosis of omasal fold (IBR).**





**Necrosis of the epithelium in cripts of lieberkühn (IBR).**